

CASE STUDY

Open Access



Harm reduction measures in a recreational gym user with anabolic androgenic steroid dependence: a case report in the context of current best clinical practice

Raphael Magnolini^{1,2*}, Sofia Laura Bottoni^{2,3}, Helena Hammer^{4,5}, Joël Capraro⁶, Philip Bruggmann^{1,2} and Oliver Senn²

Abstract

Introduction The non-medical use of androgens among recreational gym users has become a global substance use concern. Complications from use particularly appear to affect the cardiovascular system, including the development of cardiovascular events, as well as anabolic steroid-induced cardiomyopathy (ASIC). Furthermore, the development of substance dependence with a specific withdrawal syndrome appears to be common and is contributed by the development of endocrine dysfunction related to anabolic steroid-induced hypogonadism.

Case summary A 38-year-old male law enforcement officer and recreational bodybuilder presented with multiple health complaints following years of supraphysiologic androgen use and polypharmacy. Key symptoms included new-onset subacute dyspnea, dizziness, palpitations, headaches, and recurrent failed attempts at androgen cessation. Clinical findings showed abnormal blood pressure, testicular atrophy, plethoric appearance, and laboratory evidence of progressive polycythemia (hematocrit: 56.9%; normal < 49%), elevated testosterone, and suppressed luteinizing and follicle-stimulating hormones. He was at risk for muscle dysmorphia and met criteria for androgen dependence. Diagnosis confirmed ASIC. Treatment consisted of recurrent bloodletting for polycythemia, guideline-based cardiac management, and a structured endocrine regimen (tapered transdermal testosterone, oral Tamoxifen, subcutaneous human chorionic gonadotropin) to support androgen discontinuation and hormonal recovery. At 4 months, ASIC had normalized, and he was asymptomatic. However, after 6 months, he developed laboratory-confirmed idiopathic primary hypogonadism and began guideline-directed testosterone replacement. Despite more than a year of abstinence from non-medical androgen use and normalization of cardiac function, the patient died from a cardiovascular event, highlighting the possibly persistent risks of prior androgen use.

Conclusion Non-medical androgen use is a growing global issue among recreational gym-goers. The intersection of severe health risks and substance dependence highlights the urgent need for an integrated, medical and harm-reduction approach—ideally delivered in specialized primary care settings. Early detection of cardiovascular risk factors is crucial for mitigating the often-overlooked yet potentially reversible complications. A reassessment of legal and clinical measures is warranted to optimize harm reduction and provision of care. Despite best practices and a year

*Correspondence:
Raphael Magnolini
r.magnolini@arud.ch; raphael.magnolini@usz.ch

Full list of author information is available at the end of the article



© The Author(s) 2025. **Open Access** This article is licensed under a Creative Commons Attribution-NonCommercial-NoDerivatives 4.0 International License, which permits any non-commercial use, sharing, distribution and reproduction in any medium or format, as long as you give appropriate credit to the original author(s) and the source, provide a link to the Creative Commons licence, and indicate if you modified the licensed material. You do not have permission under this licence to share adapted material derived from this article or parts of it. The images or other third party material in this article are included in the article's Creative Commons licence, unless indicated otherwise in a credit line to the material. If material is not included in the article's Creative Commons licence and your intended use is not permitted by statutory regulation or exceeds the permitted use, you will need to obtain permission directly from the copyright holder. To view a copy of this licence, visit <http://creativecommons.org/licenses/by-nc-nd/4.0/>.

of abstinence from non-medical androgen use, the patient's fatal outcome underscores the critical need for further research, heightened awareness, and more robust prevention and harm reduction strategies for those affected by non-medical androgen use.

Keywords Anabolic androgenic steroids, Substance use disorder, Hypogonadism, Cardiomyopathy, Addiction, Polycythemia, Case report

Introduction

Anabolic androgenic steroid use, which includes natural androgens, e.g., testosterone, or could be synthetic derivatives to mimic the action of the endogenous male sex hormones, has become a major global health concern, particularly among young males who engage in recreational sports with the motivation of improving personal aesthetic goals [1–4]. The non-medical use of androgens most often comprises of complex supraphysiologic user patterns over months and/or chronic use over years with additional extensive polypharmacy with other medications and possible concomitant illicit substance use [2, 3]. Acute and long-term side effects from androgen use are multiple, complex, and potentially detrimental regarding health outcomes among people using these substances [3, 5–7]. Among the many complications from androgen use, particularly the cardiovascular system appears to be affected with the development of cardiovascular disease (i.e., acute myocardial infarction, venous thromboembolism, arrhythmias, heart failure [8]), as well as anabolic steroid-induced cardiomyopathy (ASIC) which has become a growing health concern [6, 9–11].

Furthermore, the development of substance dependence is common among people who are using androgens that fulfills the adapted criteria of a substance use disorder (SUD) [3, 12, 13] and most often is contributed by the development of endocrine dysfunction related to an anabolic steroid-induced hypogonadism (ASIH) [10, 14, 15]. Approximately one-third of those who start using androgens appear to develop a dependence syndrome [13]. The development of substance dependence among people who use androgens can contribute to continued use of these substances, even though negative health complications are already present, and unsuccessful attempts at androgen cessation appear to be common as well in that context [3].

This current case report presents a patient who engaged in recreational sports using androgens and was diagnosed with ASIC and screened for anabolic steroid dependence presenting in a primary care setting specialized for anabolic steroid use in Switzerland. This report highlights not only the successful reversibility of ASIC with comprehensive harm-reduction measures in an integrated primary care setting but also the sobering reality that, despite such dedicated multidisciplinary care and prolonged abstinence from non-medical androgen use, the patient ultimately suffered a fatal cardiovascular

event. This outcome underscores the persistent and potentially irreversible risks associated with prior long-term androgen use, even in the context of best-practice medical management.

Methods

A primary healthcare practice for current or past users of androgens in recreational sports was established at the Arud Centre for Addiction Medicine in Zurich (Switzerland) to improve the provision of medical care for people who are using anabolic agents from 2023 onwards [16]. The Arud Centre provides integrated medical care for patients with problematic substance use or substance use disorders. This case report's reporting and methodology follow a checklist for case reports using the CARE guidelines [17]. The complete reporting checklist is available in Supplementary Table 1.

Patient information/medical history

A 38-year-old law enforcement professional and recreational bodybuilder presented for laboratory monitoring and guidance during ongoing androgen use. Although motivated to stop, he was ambivalent about maintaining long-term abstinence. At his first visit, he reported new-onset subacute dyspnea and dizziness during strenuous exercise, as well as recurrent palpitations, headaches, excessive sweating, and reduced testicular volume. He also experienced sleep disturbances suggestive of obstructive sleep apnea and progressive male pattern hair loss. No initial mental health concerns were noted. The patient reported weekly supraphysiologic testosterone injections, prior oral use, and concurrent use of anabolic agents. He reported weekly use of testosterone propionate 300 mg/week, nandrolone phenylpropionate 300 mg/week, insulin 10 IU/day, and growth hormone (hGH) 6 IU/day. He reported not to take other medications and had no significant personal or family history of cardiovascular disease, cancer, or risk factors. He was a lifelong non-smoker, consumed minimal alcohol, and denied illicit drug use. Previous attempts to discontinue androgens, unaccompanied by medical supervision and relying on anecdotal "post-cycle therapy" to support withdrawal from non-medical androgen use [18, 19]—resulted in withdrawal symptoms (i.e., depressed mood, anxiety, insomnia, low energy, decreased libido) leading to repeated relapse. These symptoms align with anabolic

steroid-induced hypogonadism (ASIH) following prolonged androgen exposure.

Clinical findings/physical examination

On examination, the patient appeared well and not in distress. Blood pressure was elevated (160/81 mmHg), and BMI was high at 33.9 kg/m² with pronounced muscle bulk. Cardiovascular exam was normal, with no fluid overload or abnormal heart sounds. He was noted to be plethoric (florid; red-faced). Notable findings included underarm stretch marks, advanced male pattern hair loss (Hamilton-Norwood stage V), and testicular atrophy (<15 mL by self-assessment by Orchidometry). No lymphadenopathy, thyroid enlargement, or other abnormalities were detected by physical examination.

Table 1 Timeline of historical and clinical information

Timeline	Historical and clinical information
– 12 to 15 years	First time exogenous anabolic androgenic steroid use with cyclic application over a total of 8 years
0	Presentation at the primary care practice with a focused assessment of patient history, as well as physical, laboratory (blood and urine), psychometric (androgen dependence, muscle dysmorphia), instrumental (ECG) examination
+ 1 week	Referral to outpatient cardiology clinic
+ 3 weeks	Follow-up visit demonstrated progressive symptomatic polycythemia with splenomegaly treated with recurrent phlebotomy procedures
+ 4 weeks	Diagnosis of cardiomyopathy and hypertension
+ 1 month	Attempt of cessation of anabolic androgenic steroids supported with an endocrine tapering treatment protocol
+ 4 months	Follow-up cardiology examination showing normalization of ventricular structure and function and blood pressure Follow-up laboratory examination showing normalization of polycythemia
+ 6 months	Follow-up laboratory, clinical and ultrasound exam, as well as stimulation test showing sustained symptomatic endocrine dysfunction and state of hypogonadism Commencement of medical testosterone replacement therapy (TRT)
+ 7 months	Persisting risk for androgen dependence and body dysmorphia
+ 11 months	Positive OSA screening with referral to outpatient pneumology department. Diagnosis of OSA was refuted
+ 16 months	Abdominal sonography showing persisting splenomegaly Patient remained abstinent (self-reported and further objectified by laboratory markers) with continued wish for abstinence from non-medical use of anabolic androgenic steroids under medical testosterone replacement therapy
+ 19 months	The patient died from a cardiovascular event. After death, it was discovered that he had an unreported HIV diagnosis

Timeline
See Table 1.

Diagnostic assessment/measures

Further diagnostic work included laboratory (blood and urine) and ECG examinations. Table 2 presents key lab findings; all results are available in the supplementary Table 2. Abnormal results included polycythemia, mildly elevated liver enzymes, suppressed LH/FSH (indicating hypothalamic-pituitary axis suppression), elevated androgens and estrogens, and dyslipidemia characterized by low HDL. Creatine kinase was moderately elevated. Kidney function tests showed normal eGFR but albuminuria (category A2), suggesting possible kidney pathology. Other labs were unremarkable. A 12-lead ECG indicated left ventricular hypertrophy (Sokolov-Lyon index: 3.5 mV) as demonstrated in Fig. 1A. Psychometric screening identified risk for muscle dysmorphia (Muscle Dysmorphic Disorder Inventory (MDDI): 47; norm <39) and androgen dependence (adapted DSM-V: 5/7 criteria; norm <3) [20, 21]. The patient declined further psychiatric or psychotherapeutic evaluation.

For further cardiac assessment, the patient was referred to an outpatient cardiology clinic. Transthoracic echocardiography (TTE) confirmed concentric hypertrophy (septal thickness: 14 mm) with normal ejection fraction (LVEF: 65%) but reduced longitudinal strain (GLS -15%) as demonstrated in Fig. 1C, E. Mild mitral valve insufficiency was noted. Diagnosis was consistent with ASIC. A 24-h blood pressure test confirmed grade 1 hypertension (mean: 154/77 mmHg) and a hypertrophic component of cardiomyopathy would be a differential diagnosis. HFpEF was considered, but assessment was limited by tachycardia and lack of cardiac biomarkers. Exercise-induced cardiomegaly (‘athlete’s heart’) was ruled out due to reduced GLS, no cavity dilatation, and absence of other adaptations.

Nocturnal breathing difficulties prompted screening for obstructive sleep apnea (OSA); pulse oximetry indicated mild OSA (AHI: 7.0), but sleep laboratory studies later refuted this. Abdominal ultrasound showed splenomegaly (17 × 6 cm) with no other abdominal abnormalities. Testicular ultrasound revealed atrophy (12–13 cm³), minor hydrocele, and a small spermatocele (10 mm), but normal structure and perfusion. No semen analysis was performed as there was no desire for future fertility.

Therapeutic intervention
Cardiovascular and hematologic risks

Primary treatment recommendations for anabolic steroid-induced hypertension and cardiomyopathy included androgen and growth hormone cessation. Furthermore, the patient received guideline-directed antihypertensive therapy for stage 1 arterial hypertension, consisting

Table 2 Summary table of key clinical measurements

Investigation	Date						
	24.08.23	11.09.23	30.10.23	29.01.24	04.03.24	26.03.24	16.05.24
Blood pressure (mmHg)	160/81	149/71	133/67				147/78
24h blood pressure (mmHg)		154/77***		116/65****			
<i>Hematology</i>							
RCC (10e6/uL) (4.6–6.2)	5.81	6.25	5.46	4.88	4.86		5.32
Hemoglobin (Hb) (g/dL) (14–18)	17.9	19	17.4	15.4	15.5		17
Hematocrit (HCT) (%) (43–49)	52.8	56.9	50	43.1	44.4		48.1
<i>Chemistry</i>							
FSH (IU/l) (1.5–12.4)	0.3						< 0.3
LH (IU/L) (1.7–8.6)	0.3	< 0.3	0.3	9.4	9.2		< 0.3
Total Testosterone (tT) (nmol/l) (8.6–29.0)	43.6	8.3	44.5	6.5	8.2	7.7	
Free Testosterone* (fT) (pmol/l) (16.7–77.8)	166.2	27.4					
Free Testosterone** (fT) (pmol/l) (198–619)			1140	108	108	112	
Estradiol (pmol/l) (41.4–159)	258	29	176	55	23		

*Determination of bioactive testosterone by direct measurement

**Determination of free testosterone by calculation with formula of Vermeulen

***24 h blood pressure measurement conducted 21.09.2023

****24 h blood pressure measurement conducted 08.01.2024

of low-dose monotherapy with Lisinopril 5 mg daily (an ACE inhibitor) to also promote left ventricular cardiac remodeling, as per European Society of Cardiology (ESC) guidelines [22]. It is important to note that the introduction of ACE inhibitor therapy coincided with the cessation of androgens and growth hormones, which may complicate the interpretation of subsequent cardiovascular improvements. This overlap raises questions about the precise contribution of each intervention to the observed reversal of cardiovascular risk and the potential for recovery from ASIC. In a patient with established LVH (high risk), a dual antihypertensive therapy could be discussed if the systole is > 150 mmHg and androgen cessation could not be achieved. Due to a lack of evidence to establish the diagnosis of HFpEF, no treatment with an additional SGLT2 inhibitor was initiated. Other cardiovascular harm-reducing treatments included two phlebotomy treatments, also referred to as bloodletting treatments, due to progression of a severe symptomatic polycythemia (i.e., hematocrit level 56.9% (high hematocrit: > 54%) with two sessions of approximately 500 mL blood withdrawals each session. It should be noted that one bloodletting (phlebotomy) procedure was performed in the primary care setting. In contrast, an additional phlebotomy was independently conducted by the patient with the assistance of peers. This latter procedure took place within 4 weeks following the first session and occurred without the prior knowledge or supervision of the treating physician.

Anabolic steroid-induced hypogonadism

Regarding endocrine treatment of hyperestrogenism, he was initially started on Letrozole 2.5 mg daily (aromatase inhibitor; AI) to reduce aromatization of testosterone to

estradiol until androgen cessation was attempted. Thereafter, regarding cessation, there was a high risk of development of ASIH with associated withdrawal symptoms due to endocrine dysfunction of his HPT axis, as previously reported by the patient in the past. A tapering protocol according to Rahnema and colleagues was applied aiming to reduce withdrawal symptoms and to restore endogenous testosterone synthesis [14]. Treatment included a 4-week tapering of transdermal testosterone gel (60 mg to 20 mg/day), a 10-week course of Tamoxifen 20 mg daily (then reduced to 10 mg for 6 weeks) to stimulate endogenous gonadotropin release, and a 4-week rescue regimen of hCG (2000 IE, 3 times weekly). The patient was monitored over 6 months.

Follow-up and outcomes

Cardiovascular and hematologic risks

After 4 months of the guideline-directed medical therapy for arterial hypertension as well as androgen and growth hormone cessation and associated weight loss, the patient recovered clinically with normalized cardiac function and structure demonstrated in repeat ECG as well as echocardiogram (Fig. 1B, D, F) with resolution of the left ventricular hypertrophy (maximum septal thickness: 10–11 mm) and normal longitudinal function (GLS -17.5%). Cardiac biomarker (i.e., NT-proBNP) was normal. Importantly, upon the patient's cardiovascular assessment and diagnosis of anabolic steroid-induced cardiomyopathy, an abstinence motivation could be further promoted and the patient wanted to quit androgen use permanently. The arterial hypertension normalized under antihypertensive treatment and weight loss confirmed by a 24-h home blood pressure measurement (mean pressure: 116/65 mmHg). Upon androgen

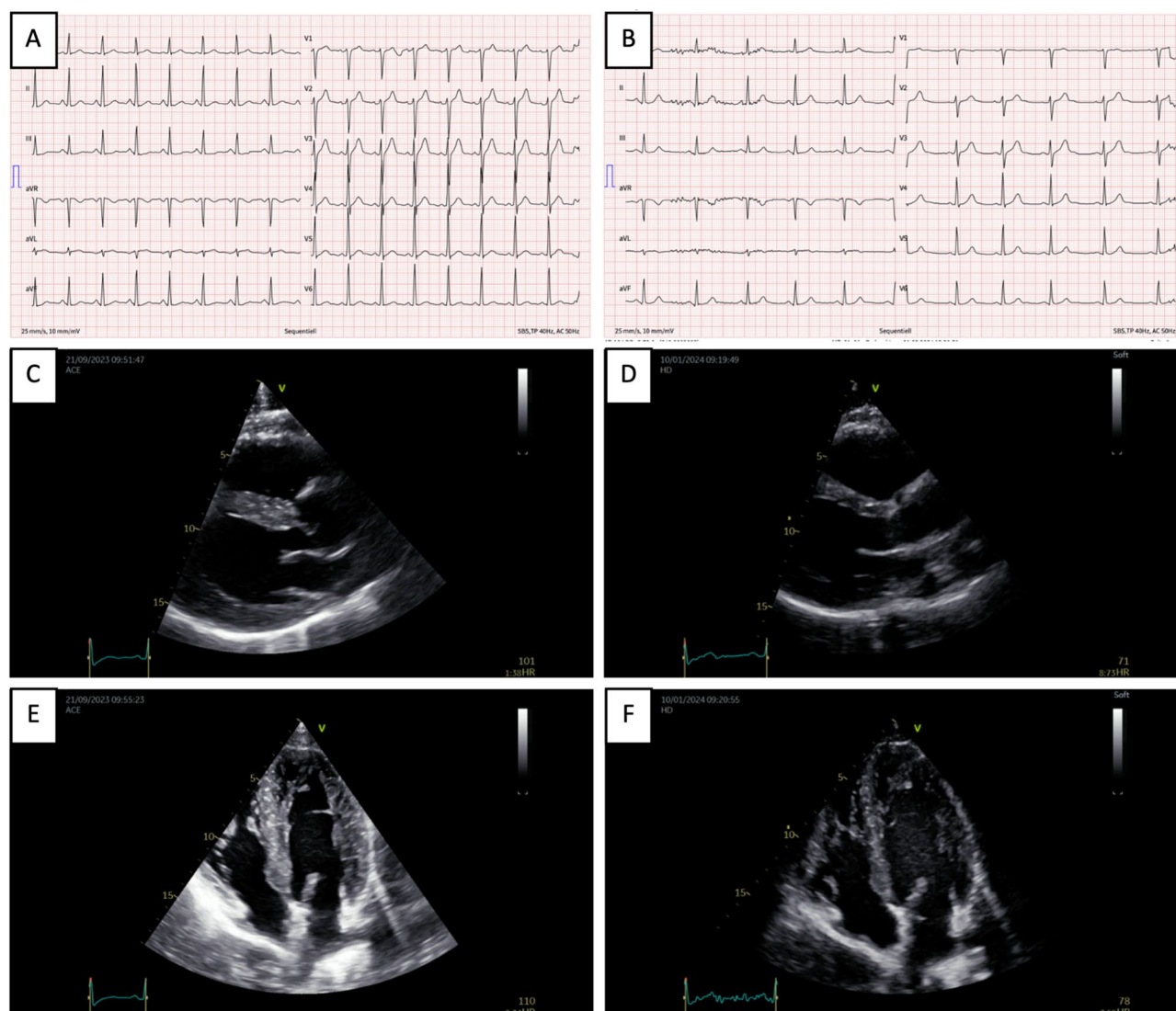


Fig. 1 Results from 12-lead electrocardiogram and cardiac ultrasound on initial presentation and follow-up after androgen cessation and antihypertensive treatment. After 8 years of cyclic androgen use, the resting ECG demonstrated signs of left ventricular hypertrophy (LVH) (A), 4 months after stopping non-medical androgen use and antihypertensive treatment, no signs of LVH could be documented by ECG (B). Echocardiographic confirmation of LVH (concentric hypertrophic left ventricle with maximum septal thickness of 14 mm), normal pump function (LVEF 65%), but reduced longitudinal function (GLS -15%) as demonstrated in the parasternal longitudinal axis view (C) and 4-chamber view (E). Pleasant cardiological course 4 months after also by echocardiographic assessment with normalization of structural changes (max. septum thickness 10-11 mm, normal pump function, normalization of longitudinal deformation (GLS -17.5%) as demonstrated in the parasternal longitudinal axis view (D) and 4-chamber view (F)

cessation and medical antihypertensive treatment the patient reported multiple orthostatic hypotensive episodes, and antihypertensive treatment was stopped with no further episodes reported. Initial phlebotomy treatment led to cardiovascular symptom improvement (i.e., headaches, dizziness, plethora) and reduction of hematocrit (50%). In combination with cessation the patient's hematocrit normalized. Splenomegaly remained stable (16.6×6 cm) at 16 months past cessation. Furthermore, dyslipidemia resolved without medical treatment, and Albuminuria improved.

Anabolic steroid-induced hypogonadism

Over 4 months of endocrine therapy, the patient's withdrawal symptoms were initially controlled. A notable peak in total testosterone (44.5 nmol/L; 30 October 2023) likely resulted from the combined use of hCG and tapering testosterone. The patient followed the protocol, experiencing only minor skin irritation from the testosterone gel, which resolved with site rotation. No other adverse events were reported. Within 6 months, symptoms of hypogonadism worsened, as evidenced by The Aging Males' Symptoms (AMS) score (43; normal ≤26) [23], low testosterone (tT: 8.2 nmol/L; fT: 108 pmol/L), and

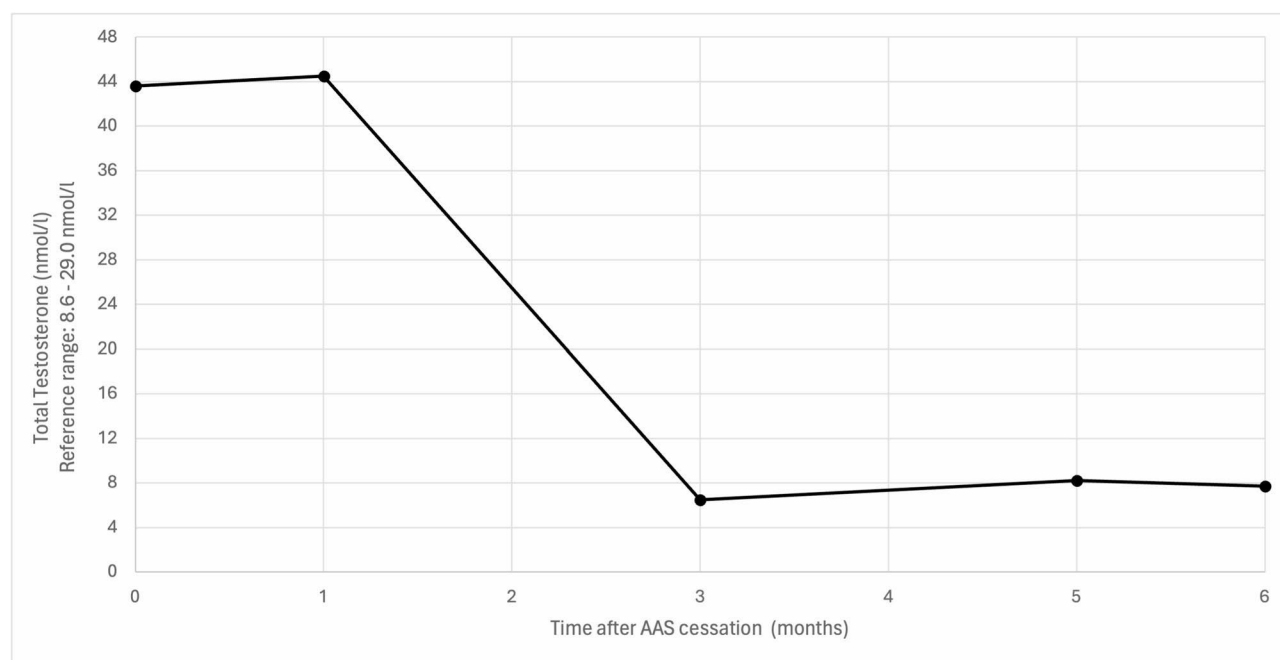


Fig. 2 Course of testosterone recovery after androgen cessation. Course of testosterone recovery after cessation of non-medical androgen use. The patient received endocrine treatment for 4 months according to a tapering protocol by Rahnema and colleagues [14]. His endogenous testosterone did not recover over an observation period of 6 months, and he developed progressive symptoms consistent with ASIH

elevated LH (9.2 IU/L). Physiological testosterone levels could not be restored, as shown in Fig. 2. A guideline-directed hCG stimulation test was conducted. Even a high dose stimulation test (5000 IE hCG as single injection) did not show a sufficient testosterone increase (tT: 1.2x; fT: 1.3x (normal: 1.8–2.5x)), reflecting gonadal failure (primary hypogonadism). In this case, the diagnosis is best classified as idiopathic primary hypogonadism. While androgen use may have been a substantial factor, other factors such as prior cryptorchidism, orchitis, genetic conditions like Klinefelter syndrome, or long-standing HIV infection and its treatment may have contributed. However, these cannot be definitively assessed anymore. This underscores both the multifactorial nature of hypogonadism and the limitations of retrospective analysis in complex cases. There is currently no consensus on the optimal duration of this endocrine treatment; thus, the patient may have benefited from a longer treatment period to facilitate endocrine recovery. As there was a high chance of relapse to non-medical use of anabolic steroid due to progressively worsening symptoms as indicated by the patient as well as the possibly of irreversible state of hypogonadism, the patient was started on standard of care testosterone replacement therapy (TRT), which led to complete resolution of symptoms associated with low testosterone (i.e., AMS: 22 points; normal: <26 points) [24]. The patient reported that he remained abstinent from non-medical androgen use until the last known consultation (>16 months after cessation). Signs

for body dysmorphic disorder (i.e., muscle dysmorphia) assessed MDDI (i.e., 44 points; normal: <39 points) persisted upon cessation, but no further psychiatric evaluation or treatment was wanted by the patient.

Postmortem insights and clinical reflections

During the manuscript review process, it was reported that the patient passed away. Although an official autopsy report is not available, based on correspondence with the hospital, the most probable cause of death was attributed to a cardiovascular event (i.e., lung embolism). A post-mortem assessment revealed that the patient had been living with HIV, a diagnosis unknown and not disclosed during the initial case study. The patient was diagnosed with HIV (CDC Stage A1) in 2012. The patient's antiretroviral treatment (ART) history includes the use of rilpivirin (25 mg), tenofovir alafenamide (25 mg) and emtricitabine (200 mg) at the time of death. Throughout the course of treatment, the patient has maintained sustained viral suppression. An external consult with a clinical pharmacology specialist was conducted, who identified a theoretical but unproven interaction between emtricitabine and testosterone therapy. Both drugs are partially eliminated by the kidneys, which could cause competition at renal transporters and affect clearance. Changes in testosterone metabolite excretion might also raise systemic androgen levels through increased recycling. Notably, this remains a theoretical consideration, as there is currently no clinical evidence to support a

significant interaction and was not evident in this patient under TRT treatment.

Importantly, while TRT is often necessary for treating hypogonadism, emerging evidence from randomized controlled trials (TRAVERSE trial) has demonstrated that TRT alone can confer an individual risk for serious cardiovascular events, most notably pulmonary embolism and atrial fibrillation [25]. This risk highlights the importance for careful patient selection and monitoring during TRT. This unexpected discovery highlights the complexity of comorbid conditions. It reinforces the importance of comprehensive medical assessments, particularly in cases involving multiple health challenges such as long-term substance use of androgens, which can lead to significant cardiovascular risks [8]. Studies have shown that non-medical androgen use may increase the likelihood of developing complications such as myocardial injury, hypertrophic cardiomyopathy, arrhythmias, and vascular damage, all of which contribute to heightened cardiovascular morbidity and mortality [8]. Additionally, HIV itself is a recognized cardiovascular risk factor as well as risk factor for acquiring hypogonadism, further emphasizing the need for integrated care [26, 27]. It is also essential to highlight that many individuals in this community frequently use fitness supplements and high-dose vitamin products procured from unregulated underground laboratories, as also possible in this case [28, 29]. These items are often counterfeit or do not contain the advertised ingredients and may harbor potentially harmful or undisclosed substances [30, 31]. The unchecked consumption of such supplements, absent proper oversight, can result in serious health complications—especially for those already at risk due to excessive androgen use.

Discussion

Epidemiology and androgen dependence

In this case report, we described a 38-year-old male recreational bodybuilder who developed ASIC and was screened for androgen dependence in a Swiss primary care setting specializing in non-medical androgen use. Tragically, during the manuscript review process, the patient passed away, with the most probable cause of death attributed to a cardiovascular event.

Globally, the lifetime prevalence of androgen use is estimated at 6.4% among males and 18.4% among recreational gym users [32]. For Switzerland, this translates to an estimated 300,000 people having used AAS at least once, though precise national data are lacking [31, 33]. Notably, about one-third (34.4%) of those who begin AAS use develop dependence or chronic use [13]. The development of a substance dependence among people that use androgens can contribute to continued use of these substances contributed by the development of body-image concerns (anabolic effects), endocrine

dysfunction (androgenic effects), as well as mechanisms shared with classical addictive drugs (hedonic effects) [3, 34]. The long-term treatment should include integrated (addiction-) medical and psychiatric care approaches as it appears that unsuccessful cessation attempts are frequent among this population [3]. Long-term androgen users are at risk of both psychological and physical dependence, with withdrawal symptoms such as mood changes, aggression, and fatigue. It is crucial to distinguish addiction—characterized by cravings and compulsive use—from physical dependence, which primarily involves withdrawal symptoms, to ensure appropriate treatment [35, 36]. The rise of anabolic steroid-use disorder is concerning, yet research into its mechanisms and optimal management remains limited. More studies are needed to improve and validate diagnostic criteria and develop effective treatments that support hypothalamic-pituitary axis recovery while addressing the broader neurobiological and hormonal effects of androgen use.

Given the high prevalence and growing popularity of androgens, healthcare providers must be knowledgeable about the individual and public health risks associated with these substances. Many individuals self-medicate and seek advice from peers or online forums, turning to specialized or emergency care only for severe side effects [37]. Hospitalization rates for androgen users are significantly higher than for non-users [38]. Barriers to accessing regular healthcare include fear of stigma or judgment, lack of trust in healthcare professionals, concerns about legal repercussions, and difficulty obtaining necessary medications for androgen-related complications [37].

Cardiovascular and hematologic risks

This patient received integrated care focused on minimizing cardiovascular and hematologic risks from long-term androgen use. Routine monitoring included regular assessments of cardiac function and blood parameters. Despite cessation of androgen use and harm reduction measures, the patient ultimately died due to a cardiovascular event—most likely a pulmonary embolism. This outcome underscores the persistent and possibly substantial risks faced by individuals with a prolonged history of androgen use and coexisting medical conditions. Among the known health risks of non-medical androgen use, cardiovascular complications appear to be particularly substantial [6, 8–11]. While large trials found TRT in hypogonadal men was not inferior to placebo regarding major cardiac events although use may carry an elevated risk for pulmonary embolism, the impact of non-medical, supraphysiologic use remains unclear and may depend on dose and compounds used [25, 39]. Case-control studies indicate androgen users have a higher mortality risk, especially from cardiovascular causes, though high-quality data are limited [8, 29, 38, 40, 41].

The non-medical use of AAS may result in a series of complications on the cardiovascular system including vascular injury as well as anabolic steroid-induced cardiomyopathy with/without heart failure from myocardial injury (i.e., atherogenic and prothrombotic effects, and vasoconstriction) as well as biventricular dysfunction (i.e., hypertrophic changes, increased blood pressure, and cardiac remodeling) which may culminate in those patients alongside more risk factors such as arrhythmias, obstructive sleep apnea, or polycythemia [8, 11, 42–45]. The underlying pathobiology based on the current understanding is summarized in the supplementary Table 4. Cardiovascular risks as well as risk for cardiomyopathy can accumulate in this population with the concomitant use of image- and performance-enhancing drugs, such as growth hormones in this patient [46]. This underlines that cardiovascular case findings may be frequent among patients using androgens and screening recommendations regarding cardiovascular risk factors should be conducted among this population. The risk of people using androgens suffering from acute myocardial infarction at a young age may be 3% [47]. The development of ASIC may be a frequent, yet an underrecognized and underreported outcome [8, 16]. The reversibility of ASIC varies and may depend on different factors (i.e., type, strength, duration of androgen use, polypharmacy with other anabolic agents, and concomitant illicit substance use) and is conversely discussed within the medical literature [11]. Timely diagnosis as well as adequate early treatment initiation may be crucial to avoid disease progression and irreversible damage from a complication that most often goes unnoticed in early stages. Findings in ECG exams are common among sportspeople as well as people using androgens. The differentiation of normal (e.g., athletes' heart) and abnormal (e.g., LVH) ECG findings can be challenging, although different ECG indices could be applied (e.g., Sokolow-Lyon index, modified Sokolow-Lyon index, Cornell voltage QRS duration product, Romhilt-Estes score, Seattle Criteria) [48–51]. Given the prevalence of ECG abnormalities among athletes and androgen users, we recommend discussing findings with a cardiology specialist and considering prompt low-threshold referral for additional diagnostics, such as echocardiography. Notably, a timely referral and the visualization of cardiomyopathy via echocardiography prompted this patient to reconsider substance use and helped foster ongoing abstinence. This intervention may have contributed to the complete reversibility observed.

Notably, the patient exhibited significant muscle mass objectified by BMI assessment. While more detailed assessments of body composition were not standard at the clinic, efforts are underway to implement bioimpedance analysis or abdominal circumference measurement for improved monitoring.

Polycythemia, or erythrocytosis, is a common finding in patients using androgens, marked by elevated hematocrit (>49% for men) or hemoglobin (>165 g/L for men) [52]. This can contribute to increased cardiovascular risk through complications like microvascular issues and thrombotic events [2, 53, 54]. There is currently no clear clinical guidance for managing polycythemia in those using supraphysiologic androgen doses, so regular monitoring for symptoms (such as headaches, visual changes, hypertension, and splenomegaly) is important [52, 55]. Hematocrit and blood pressure should be checked periodically. For hematocrit levels above 52%, a reduction in androgen dose or bloodletting may be considered to lower cardiovascular risk [45]. We advocate for accessible phlebotomy when the hematocrit exceeds 52%, especially if the patient is symptomatic or has a hematocrit above 54%. Other contributors, such as diuretics, stimulant use, and dehydration, can further exacerbate polycythemia [52]. Persistent cases warrant evaluation for alternative causes (e.g., polycythemia vera; Jak2 mutation status). Obstructive sleep apnea (OSA) may also play a role and should be screened using tools like the STOP-BANG questionnaire [44, 45]. Although therapeutic phlebotomy is sometimes used for androgen-induced erythrocytosis, its efficacy and safety remain unclear, and risks such as iron depletion, which may increase thrombotic risk, must be weighed with the patient [56].

Splenomegaly in this patient may have resulted from several converging factors. While long-term polycythemia secondary to androgen use possibly promoted myeloproliferative processes, it is also important to consider that HIV infection, present in this individual, can independently contribute to splenic enlargement through chronic immune activation [57]. Furthermore, a history of growth hormone use could induce visceromegaly, further compounding splenic enlargement [46]. In this case, alternative causes of splenomegaly such as neoplastic, infectious, or congestive etiologies, including Polycythemia vera, were deemed less likely, and no further investigations (e.g., JAK2 mutation status) were pursued.

Anabolic steroid-induced hypogonadism

The development of ASI after use of androgens, a central or secondary form of the male hypogonadism by inhibition of the hypothalamic-pituitary-gonadal hormone axis, appears to be a hallmark in the pathology of this dependence syndrome and results in a functional incompetence of the testes with subnormal or impaired testosterone levels [14, 34, 58, 59]. Furthermore, studies suggest possibly irreversible down-regulation of androgen receptors or androgen receptor signaling mechanisms, possibly representing end-organ resistance as well as direct testicular toxicity from synthetic androgen use, leading to possible irreversible primary hypogonadism

or gonadal failure [14, 15]. ASIH may cause potentially serious negative consequences in males, contributing to a unique withdrawal syndrome after androgen cessation, associated with dependency as well as potentially long-lasting and/or permanent symptoms [23]. There is currently limited evidence on therapeutic approaches to facilitate safe withdrawal. Yet, many people still tend to self-treat this withdrawal syndrome through a practice often referred to as “post-cycle therapy” or ‘PCT’ [18, 19]. PCT is a non-medical term used by men using androgens to describe a heterogeneous group of substances used based on anecdotal patterns, most often comprising of a course of human chorionic gonadotrophin (hCG), and/or selective estrogen receptor modulators (SERM) or aromatase inhibitors (AI) [2, 14, 18]. Current protocols for treating anabolic steroid-induced hypogonadism (ASIH) rely on expert opinion and limited studies [14, 18, 19, 60]. While some benefits have been shown, key questions—such as the proper hCG dosage—remain unresolved, with practices varying from 1000 to 3000 IU three times weekly; in Switzerland, 2000 IU is a standard dose. Robust randomized controlled trials are needed to guide dosing and long-term management, ensuring evidence-based care. There is emerging and conflicting literature on the provision of this endocrine therapy regarding the effectiveness as well as on the recovery of testicular function following AAS cessation. Among long-term users of androgens, withdrawal symptoms appear to be very common, frequently prolonged, associated with morbidity, and in many cases the full biochemical recovery is highly variable, often difficult to achieve and in some cases may never fully recover [10, 14, 15, 18, 19, 58, 60, 61]. Medical and pharmacological interventions may support the recovery, although the recovery of ASIH may depend on many factors (e.g., age, degree of androgen use) [14, 58]. We support the provision of these current strategies with caution and clear inclusion criteria, as these treatments are also well tolerated based on the current best medical literature, or absence thereof [14, 25, 60, 62–64]. In patients where recovery of testosterone production is unsuccessful, substitution therapy with TRT should be introduced as standard medical care when clinically indicated. Unfortunately, current evidence does not provide clear guidance on the optimal duration to wait for spontaneous recovery. In this case, shared decision making played a crucial role and was based on a comprehensive evaluation of clinical and laboratory findings, the progression of symptoms, and the risk of relapse into non-medical androgen use.

The role of primary care

The tragic outcome in this case—a patient’s death despite cessation of androgen use and harm reduction efforts—emphasizes the urgent necessity for early, low-threshold

access to comprehensive, integrated medical services. Timely intervention through accessible and coordinated care is essential to identify, monitor, and address the complex health risks associated with non-medical androgen use before irreversible harm occurs. This case powerfully illustrates that without prompt engagement in integrated medical support, the window for preventing fatal outcomes may close all too soon. The primary care setting offers low-threshold access to healthcare, chronic care management, and care coordination. A case finding through low-threshold access (i.e., the patient’s wish for a laboratory check in our case) resulted in a timely diagnosis and management of cardiovascular risk factors, which may be crucial for the possible reversibility of ASIH and the prevention of possible detrimental cardiovascular health outcomes among this population. As demonstrated in this patient, the provision of harm-reducing measures within these settings allows people who use these substances to engage with (addiction) medical and behavioral interventions and to reduce these risks as well as the risk of relapse, instead of leaving patients in the care of peers without medical backgrounds. There is currently a lack of guidance and consensus on the optimal provision of harm-reducing measures. Future studies should focus on optimizing the clinical guidance for optimal care provision to people who use androgens in recreational sports in primary care settings. Importantly, the delivery of medical care often involves legal aspects that need to be considered and may instill fear regarding legal repercussions in both the treating doctor and the patient, which limits having an open discussion regarding this substance use [16, 65, 66]. Considering the patient’s death, it becomes even more critical to implement strategies that avert both morbidity and mortality among individuals with a history of non-medical androgen use. Proactive identification, harm reduction, and timely intervention are crucial to addressing the profound risks faced by this population and to preventing such devastating outcomes in the future.

Conclusions

Despite comprehensive, evidence-based clinical management, this young male patient with a history of recreational sports participation, long-term non-medical androgen use, HIV infection, and growth hormone supplementation ultimately died of a cardiovascular event. His care included cessation of androgens, initiation of endocrine treatment for ASIH with a 16-week protocol of tamoxifen, testosterone gel, and hCG, followed by substitution-based TRT, all provided within an integrated framework of medical, psychiatric, and addiction care. Additionally, his management involved thorough screening for comorbid medical conditions and active treatment of polycythemia. Although guideline-directed medical

therapy led to normalization of cardiac structures and function, this case tragically mirrors the high risk of cardiovascular death among non-medical androgen users. This outcome underscores the urgent need for enhanced prevention, early intervention, and harm-reduction strategies to help reduce morbidity and prevent fatal deaths among individuals using androgens.

Learning points

- Early harm reduction is vital: Timely initiation of comprehensive harm-reduction strategies in primary care is crucial to possibly prevent irreversible health consequences and fatal outcomes among individuals using non-medical androgens.
- Integrated care may improve outcomes: Coordinated, multidisciplinary management—including medical, psychiatric, and addiction support—may enhance engagement and recovery, addressing both substance dependence and associated health risks.
- Cardiovascular and hematologic risks can be substantial: Non-medical androgen use can result in severe complications, such as androgen-induced secondary polycythemia, cardiomyopathy, and cardiovascular events, which require early identification and intervention to avoid long-term damage.
- Management of ASIH is challenging: ASIH is common, often persistent, and requires individualized management; clear clinical protocols and evidence-based guidance are currently lacking and urgently needed regarding the high and increasing prevalence of this substance use.
- Primary care is a critical access point to healthcare services: Low-threshold, accessible primary care settings are essential for case finding, chronic disease monitoring, coordination of care, and provision of harm-reducing interventions to engage this high-risk population in ongoing care.

Patient perspective

I'm 39 years old now and started [androgen use] about 12–15 years ago. The reason to start was to increase [physical] performance and for faster increase in muscle mass. Since I didn't feel any major side effects other than sleep problems, there was no reason to stop [androgen use]. The family doctor had already diagnosed high blood pressure and too much blood [polycythemia] and discussed it with me, but that was it. There was no treatment or anything like that. There are no heart problems in my family, and I have never had any problems with it [heart]. I didn't notice many symptoms. The diagnosis described above [polycythemia] was made through a regular blood exam.

Finally, I talked to friends who heard about the program [medical consultation for users of anabolic androgenic steroids] at Arud [primary care practice] and I signed up. Additional tests were carried out there and I was then referred to a specialist [outpatient cardiology clinic]. I was told about it [cardiomyopathy] by the Heart Clinic, Dr. H. Hammer, and was prescribed the drug Lisinril 5 mg [Lisinopril; ACE inhibitor] for 6 months. However, after about 4 months I had to stop taking the medication because my high blood pressure was too low! After another examination, it was determined that the heart muscle had recovered, and I no longer had to take the medication. I am no longer being treated for heart issues. In this regard, I also feel good and healthy! No further investigations are planned.

I'm sure it was important and right that I sought medical advice and agreed to it. Ultimately, you can convince yourself that you are healthy for a long time, but only the doctors can determine what your insides really look like. I also have to say that I had great trust in everyone involved and I would like to thank you very much for that!

Abbreviations

AMS Questionnaire	Aging males' symptoms questionnaire
ASIC	Anabolic steroid-induced cardiomyopathy
ASIH	Anabolic-steroid-induced hypogonadism
CARE	CASE RReport (Checklist for case report information)
ECG	Electrocardiogram
ft	Free testosterone
hCG	Human chorionic gonadotropin
HIV	Human immunodeficiency virus
JAK2	Janus kinase 2
LH	Luteinizing hormone
OSA	Obstructive sleep apnea
PCT	Post-cycle therapy
tT	Total testosterone
TRT	Testosterone replacement therapy

Supplementary Information

The online version contains supplementary material available at <https://doi.org/10.1186/s12954-025-01294-w>.

Supplementary Material 1.

Acknowledgements

We would like to express our sincere gratitude to Prof. Dr. med. Stefan Weiler (specialist in general internal medicine and clinical pharmacology and toxicology) for his expert pharmacologic and toxicologic assessment conducted post-mortem in relation to this case report. His invaluable insights and specialized analysis greatly contributed to the depth and rigor of our findings.

Author contributions

RM/PB/OS conceived of the case report. RM/SLB conducted the literature search. RM/SLB extracted patient information. HH/JC provided specialised medical expertise. OS provided methodological expertise on primary care. RM prepared figures. RM created the main manuscript draft. All authors contributed to refinement and approved the final manuscript.

Funding

No funding was received for conducting this study.

Data availability

The datasets supporting the conclusions of this article are included within the article and its additional files.

Declarations

Ethics approval and consent to participate

This case report does not require ethical approval.

Consent for publication

The patient has read the final manuscript for initial submission and provided informed consent for publication.

Competing interests

The authors have no relevant financial or non-financial interests to disclose. We can report that there is no conflict of interest.

Author details

¹Arud Centre for Addiction Medicine, Schuetzengasse 31, 8001 Zurich, Switzerland

²Institute of Primary Care, University Hospital Zurich, University of Zurich, Zurich, Switzerland

³Faculty of Medicine, University of Zurich, Zurich, Switzerland

⁴HerzGefässZentrum im Park, Hirslanden Group, Zurich, Switzerland

⁵Herzpraxis Stadelhofen, Zurich, Switzerland

⁶Department of Endocrinology, Diabetology and Metabolism, Cantonal Hospital Aarau, Aarau, Switzerland

Received: 9 March 2025 / Accepted: 1 August 2025

Published online: 21 August 2025

References

1. Ip EJ, Lu DH, Barnett MJ, Tenerowicz MJ, Vo JC, Perry PJ. Psychological and physical impact of anabolic-androgenic steroid dependence. *Pharmacotherapy*. 2012;32(10):910–9.
2. Bonnacaze AK, O'Connor T, Burns CA. Harm reduction in male patients actively using anabolic androgenic steroids (AAS) and performance-enhancing drugs (PEDs): a review. *J Gen Intern Med*. 2021;36(7):2055–64.
3. Bonnacaze AK, O'Connor T, Aloï JA. Characteristics and attitudes of men using anabolic androgenic steroids (AAS): a survey of 2385 men. *Am J Mens Health*. 2020;14(6): 1557988320966536.
4. Kanayama G, Pope HG. History and epidemiology of anabolic androgens in athletes and non-athletes. *Mol Cell Endocrinol*. 2018;464:4–13.
5. Mullen C, Whalley BJ, Schifano F, Baker JS. Anabolic androgenic steroid abuse in the United Kingdom: an update. *Br J Pharmacol*. 2020. <https://doi.org/10.1111/bph.14995>.
6. Nieschlag E, Vorona E. Doping with anabolic androgenic steroids (AAS): adverse effects on non-reproductive organs and functions. *Rev Endocr Metab Disord*. 2015;16(3):199–211.
7. Christou MA, Christou PA, Markozannes G, Tsatsoulis A, Mastorakos G, Tigas S. Effects of anabolic androgenic steroids on the reproductive system of athletes and recreational users: a systematic review and meta-analysis. *Sports Med*. 2017;47(9):1869–83.
8. Windfeld-Mathiasen J, Heerfordt IM, Dalhoff KP, Trærup Andersen J, Andersen MA, Johansson KS, et al. Cardiovascular disease in anabolic androgenic steroid users. *Circulation*. 2025;151:828–34.
9. Albano GD, Amico F, Cocimano G, Liberto A, Maglietta F, Esposito M, et al. Adverse effects of anabolic-androgenic steroids: a literature review. *Healthcare*. 2021;9(1): 97.
10. Esposito M, Salerno M, Calvano G, Agliozzo R, Ficarra V, Sessa F, et al. Impact of anabolic androgenic steroids on male sexual and reproductive function: a systematic review. *Panminerva Med*. 2023;65(1):43–50.
11. Fadah K, Gopi G, Lingireddy A, Blumer V, Dewald T, Mentz RJ. Anabolic androgenic steroids and cardiomyopathy: an update. *Front Cardiovasc Med*. 2023;10: 1214374.
12. Pope HG, Kanayama G, Athey A, Ryan E, Hudson JI, Baggish A. The lifetime prevalence of anabolic-androgenic steroid use and dependence in Americans: current best estimates. *Am J Addict*. 2014;23(4):371–7.
13. Skauen JE, Pallesen S, Bjørnebekk A, Chegeni R, Syvertsen A, Petróczi A, et al. Prevalence and correlates of androgen dependence: a meta-analysis, meta-regression analysis and qualitative synthesis. *Curr Opin Endocrinol Diabetes Obes*. 2023. <https://doi.org/10.1097/MED.0000000000000822>.
14. Rahnama CD, Lipshultz LI, Crosnoe LE, Kovac JR, Kim ED. Anabolic steroid-induced hypogonadism: diagnosis and treatment. *Fertil Steril*. 2014;101(5):1271–9.
15. Solanki P, Eu B, Smith J, Allan C, Lee K. Physical, psychological and biochemical recovery from anabolic steroid-induced hypogonadism: a scoping review. *Endocr Connect*. 2023. <https://doi.org/10.1530/EC-23-0358>.
16. Magnolini R, Kossinna K, Bjasch D, Kruijver M, Bruggmann P, Senn O. Feasibility of implementing current best clinical practice for people who are using anabolic androgenic steroids within a Swiss primary care practice: a quality assurance study. *Swiss Med Wkly*. 2025;155(2): 4225. <https://doi.org/10.57187/s.4225>.
17. Gagnier JJ, Kienle G, Altman DG, Moher D, Sox H, Riley D. The CARE guidelines: consensus-based clinical case reporting guideline development. *Headache*. 2013;53(10):1541–7.
18. Grant B, Kean J, Vali N, Campbell J, Maden L, Bijral P, et al. The use of post-cycle therapy is associated with reduced withdrawal symptoms from anabolic-androgenic steroid use: a survey of 470 men. *Subst Abuse Treat Prev Policy*. 2023;18(1): 66.
19. Grant B, Campbell J, Pradeep A, Burns AD, Bassett P, Abbara A, et al. Factors predicting normalization of reproductive hormones after cessation of anabolic-androgenic steroids in men: a single center retrospective study. *Eur J Endocrinol*. 2023;189(6):601–10.
20. Zeck A, Welter V, Alatas H, Hildebrandt T, Lahmann C, Hartmann A. Muscle dysmorphic disorder inventory (MDDI): validation of a German version with a focus on gender. *PLoS ONE*. 2018;13(11): e0207535.
21. Kanayama G, Brower KJ, Wood RI, Hudson JI, Pope HG. Issues for DSM-V: clarifying the diagnostic criteria for anabolic-androgenic steroid dependence. *Am J Psychiatry*. 2009;166(6):642–5.
22. McEvoy JW, McCarthy CP, Bruno RM, Brouwers S, Canavan MD, Ceconi C, et al. 2024 ESC guidelines for the management of elevated blood pressure and hypertension. *Eur Heart J*. 2024;45(38):3912–4018.
23. Heinemann LA, Saad F, Zimmermann T, Novak A, Myon E, Badia X, et al. The Aging Males' Symptoms (AMS) scale: update and compilation of international versions. *Health Qual Life Outcomes*. 2003;1:15.
24. Corona G, Goulis DG, Huhtaniemi I, Zitzmann M, Toppari J, Forti G, et al. European academy of andrology (EAA) guidelines on investigation, treatment and monitoring of functional hypogonadism in males: endorsing organization: European Society of Endocrinology. *Andrology*. 2020;8(5):970–87.
25. Lincoff AM, Bhasin S, Flevaris P, Mitchell LM, Basaria S, Boden WE, et al. Cardiovascular safety of testosterone-replacement therapy. *N Engl J Med*. 2023;389(2):107–17.
26. De Vincentis S, Rochira V. Update on acquired hypogonadism in men living with HIV: pathogenesis, clinic, and treatment. *Front Endocrinol (Lausanne)*. 2023;14: 1201696.
27. Afolabi JM, Kirabo A. HIV and cardiovascular disease. *Circ Res*. 2024;134(11):1512–4.
28. Parente Filho SLA, Gomes PEAC, Forte GA, Lima LLL, Silva Júnior GBD, Meneses GC, et al. Kidney disease associated with androgenic-anabolic steroids and vitamin supplements abuse: be aware! *Nefrologia (Engl Ed)*. 2020;40(1):26–31.
29. Smoliga JM, Wilber ZT, Robinson BT. Premature death in bodybuilders: what do we know? *Sports Med*. 2023;53(5):933–48.
30. Magnolini R, Falcato L, Cremonesi A, Schori D, Bruggmann P. Fake anabolic androgenic steroids on the black market - a systematic review and meta-analysis on qualitative and quantitative analytical results found within the literature. *BMC Public Health*. 2022;22(1): 1371.
31. Kruijver M, Bruggmann P, Magnolini R. Evidence of use and users of image- and performance-enhancing drugs in sports in Switzerland: a scoping literature review and implications for Swiss drug policy. *Swiss Med Wkly*. 2023;153: 40080.
32. Sagoe D, Molde H, Andreassen CS, Torsheim T, Pallesen S. The global epidemiology of anabolic-androgenic steroid use: a meta-analysis and meta-regression analysis. *Ann Epidemiol*. 2014;24(5):383–98.
33. Iff S, Butzke I, Quednow B, Gupta R, Imboden C, Clausen M. «Image and performance enhancing drugs» im Freizeitsport. *Swiss Med Forum*. 2021;21:843–7.
34. Kanayama G, Brower KJ, Wood RI, Hudson JI, Pope HG. Anabolic-androgenic steroid dependence: an emerging disorder. *Addiction*. 2009;104(12):1966–78.

35. Szalavitz M, Rigg KK, Wakeman SE. Drug dependence is not addiction-and it matters. *Ann Med*. 2021;53(1):1989–92.
36. Horowitz MA, Taylor D. Addiction and physical dependence are not the same thing. *Lancet Psychiatry*. 2023;10(8):e23.
37. Harvey O, Keen S, Parrish M, van Teijlingen E. Support for people who use anabolic androgenic steroids: a systematic scoping review into what they want and what they access. *BMC Public Health*. 2019;19(1): 1024.
38. Horwitz H, Andersen JT, Dalhoff KP. Health consequences of androgenic anabolic steroid use. *J Intern Med*. 2019;285(3):333–40.
39. McCullough D, Webb R, Enright KJ, Lane KE, McVeigh J, Stewart CE, et al. How the love of muscle can break a heart: impact of anabolic androgenic steroids on skeletal muscle hypertrophy, metabolic and cardiovascular health. *Rev Endocr Metab Disord*. 2021;22(2):389–405.
40. Windfeld-Mathiasen J, Heerfordt IM, Dalhoff KP, Andersen JT, Horwitz H. Mortality among users of anabolic steroids. *JAMA*. 2024. <https://doi.org/10.1001/jama.2024.3180>.
41. Hernández-Guerra AI, Tapia J, Menéndez-Quintanal LM, Lucena JS. Sudden cardiac death in anabolic androgenic steroids abuse: case report and literature review. *Forensic Sci Res*. 2019;4(3):267–73.
42. Smit DL, Voogel AJ, den Heijer M, de Ronde W. Anabolic androgenic steroids induce reversible left ventricular hypertrophy and cardiac dysfunction: echocardiography results of the HAARLEM study. *Front Reprod Health*. 2021;3:732318.
43. Doleeb S, Kratz A, Salter M, Thohan V. Strong muscles, weak heart: testosterone-induced cardiomyopathy. *ESC Heart Fail*. 2019;6(5):1000–4.
44. Mohsenin V. Obstructive sleep apnea and hypertension: a critical review. *Curr Hypertens Rep*. 2014;16(10): 482.
45. Basheer B, Ila V, Barros R, Mesquita F, Lopes LS, Lima VFN, et al. Management of adverse effects in testosterone replacement therapy. *Int Braz J Urol*. 2025. <https://doi.org/10.1590/s1677-5538.1bju.2025.9904>.
46. Lugo G, Pena L, Cordido F. Clinical manifestations and diagnosis of acromegaly. *Int J Endocrinol*. 2012;2012: 540398.
47. Baggish AL, Weiner RB, Kanayama G, Hudson JI, Lu MT, Hoffmann U, et al. Cardiovascular toxicity of illicit anabolic-androgenic steroid use. *Circulation*. 2017;135(21):1991–2002.
48. Drezner JA, Sharma S, Baggish A, Papadakis M, Wilson MG, Prutkin JM, et al. International criteria for electrocardiographic interpretation in athletes: consensus statement. *Br J Sports Med*. 2017;51(9):704–31.
49. Drezner JA, Ackerman MJ, Anderson J, Ashley E, Asplund CA, Baggish AL, et al. Electrocardiographic interpretation in athletes: the “Seattle criteria.” *Br J Sports Med*. 2013;47(3):122–4.
50. Estes EH, Zhang ZM, Li Y, Tereshchenko LG, Soliman EZ. The romhilt-estes left ventricular hypertrophy score and its components predict all-cause mortality in the general population. *Am Heart J*. 2015;170(1):104–9.
51. Courand PY, Lantelme P, Gosse P. Electrocardiographic detection of left ventricular hypertrophy: time to forget the Sokolow-Lyon index? *Arch Cardiovasc Dis*. 2015;108(5):277–80.
52. Pillai AA, Fazal S, Mukkamalla SKR, Babiker HM. Polycythemia. In: StatPearls [Internet]. Treasure Island (FL): StatPearls Publishing; 2025.
53. Michiels JJ. Erythromelalgia and vascular complications in polycythemia vera. *Semin Thromb Hemost*. 1997;23(5):441–54.
54. Chang S, Münster AB, Gram J, Sidelmann JJ. Anabolic androgenic steroid abuse: the effects on thrombosis risk, coagulation, and fibrinolysis. *Semin Thromb Hemost*. 2018;44(8):734–46.
55. Ohlander SJ, Varghese B, Pastuszak AW. Erythrocytosis following testosterone therapy. *Sex Med Rev*. 2018;6(1):77–85.
56. Bond P, Verdegaa T, Smit DL. Testosterone therapy-induced erythrocytosis: can phlebotomy be justified? *Endocr Connect*. 2024;13(10):e240283.
57. Furrer H. Prevalence and clinical significance of splenomegaly in asymptomatic human immunodeficiency virus type 1-infected adults. *Swiss HIV cohort study*. *Clin Infect Dis*. 2000;30(6):943–5.
58. Vilar Neto JO, da Silva CA, Bruno da Silva CA, Pinto DV, Caminha JSR, de Matos RS, et al. Anabolic androgenic steroid-induced hypogonadism, a reversible condition in male individuals? A systematic review. *Andrologia*. 2021;53(7):e14062.
59. van Breda E, Keizer HA, Kuipers H, Wolffenbuttel BH. Androgenic anabolic steroid use and severe hypothalamic-pituitary dysfunction: a case study. *Int J Sports Med*. 2003;24(3):195–6.
60. Havnes IA, Henriksen HCB, Johansen PW, Bjørnebekk A, Neupane SP, Hisdal J, et al. Off-label use of clomiphene citrate to treat anabolic androgenic steroid induced hypogonadism upon cessation among men (CloTASH) - a pilot study protocol. *MethodsX*. 2024;13: 102810.
61. Smit DL, Buijs MM, de Hon O, den Heijer M, de Ronde W. Disruption and recovery of testicular function during and after androgen abuse: the HAARLEM study. *Hum Reprod*. 2021;36(4):880–90.
62. Snyder PJ, Bauer DC, Ellenberg SS, Cauley JA, Buhr KA, Bhasin S, et al. Testosterone treatment and fractures in men with hypogonadism. *N Engl J Med*. 2024;390(3):203–11.
63. Bhasin S, Thompson IM. Prostate risk and monitoring during testosterone replacement therapy. *J Clin Endocrinol Metab*. 2024;109(8):1975–83.
64. Henriksen HCB, Jørgensen AP, Bjørnebekk A, Neupane SP, Havnes IA. Clomiphene citrate and optional human chorionic gonadotropin for treating male hypogonadism arising from long-term anabolic-androgenic steroid use—a pilot study. *Performance Enhancement Health*. 2024. <https://doi.org/10.1016/j.peh.2024.100283>.
65. Piatkowski T, Gibbs N, Dunn M. Beyond the law: on Etiacaasu, help-seeking and health outcomes in Australia. *J Criminol*. 2024;57:62–82. <https://doi.org/10.1177/26338076231209044>.
66. Dunn M, Piatkowski T, Whiteside B, Eu B. Exploring the experiences of general practitioners working with patients who use performance and image enhancing drugs. *Perform Enhanc Health*. 2023;11(2):100247. <https://doi.org/10.1016/j.peh.2023.100247>.
67. Gagnier JJ, Kienle G, Altman DG, Moher D, Sox H, Riley D. The CARE guidelines: consensus-based clinical case reporting guideline development. *Glob Adv Health Med*. 2013;2(5):38–43.
68. Seara FAC, Olivares EL, Nascimento JHM. Anabolic steroid excess and myocardial infarction: from ischemia to reperfusion injury. *Steroids*. 2020;161: 108660.
69. Liu JD, Wu YQ. Anabolic-androgenic steroids and cardiovascular risk. *Chin Med J (Engl)*. 2019;132(18):2229–36.
70. Smit DL, Bond P, de Ronde W. Health effects of androgen abuse: a review of the HAARLEM study. *Curr Opin Endocrinol Diabetes Obes*. 2022;29(6):560–5.
71. Bond P, Smit DL, de Ronde W. Anabolic-androgenic steroids: How do they work and what are the risks? *Front Endocrinol (Lausanne)*. 2022;13:1059473.
72. Gagnon LR, Sadasivan C, Perera K, Oudit GY. Cardiac complications of common drugs of abuse: pharmacology, toxicology, and management. *Can J Cardiol*. 2022;38(9):1331–41.
73. Ilonze OJ, Enyi CO, Ilonze CC. Cardiomyopathy and heart failure secondary to anabolic-androgen steroid abuse. *Proc (Bayl Univ Med Cent)*. 2022;35(3):363–5.

Publisher's Note

Springer Nature remains neutral with regard to jurisdictional claims in published maps and institutional affiliations.